

CORRESPONDENCE

Successful treatment of erosive vulvovaginal lichen planus with topical tacrolimus

SIR, We report two women with erosive vulvovaginal lichen planus (LP) who responded within 4 weeks to topical tacrolimus. Both women were 54 years old when seen at our Institution. They had been suffering from erosive LP for 6 and 3 years, respectively; both had oral, vulval (Fig. 1a) and vaginal involvement. Vulval histology showed hypergranulosis, irregular acanthosis, vacuolar changes of the basal cells, cytooid bodies and a band-like lymphocytic infiltrate at the dermoepidermal junction, supporting the diagnosis of LP in both cases.

Both patients had received various treatments (very potent topical corticosteroids, systemic corticosteroids, dapsone, griseofulvin, acitretin and hydroxychloroquine) for their erosive LP prior to treatment with topical tacrolimus, without major improvement.

We started treatment with 0.1% topical tacrolimus (Prograf capsules, Fujisawa) in ointment simplex FNA (paraffin ointment: cetostearyl alcohol 2.5 g, adeps lanae 6 g, paraffinum liquidum 40 g, vaselinum album ad 100 g) three times weekly in the evening: one fingertip of ointment (0.5 g) was applied to the vulva and 2 g was applied to the vagina using a vaginal applicator. The patients were reviewed monthly and treatment response was assessed by the patient and by the investigator who had seen the patient at the initial visit. All other treatments for the genital LP were stopped when topical tacrolimus was initiated. We noticed an improvement of the vulval symptoms after 4 weeks of topical tacrolimus

application. The vulval mucosa was less erosive and less painful; the vagina was still erosive but less contact bleeding was noticed by the patient. Tacrolimus was continued and the symptoms improved after another 4 weeks of treatment. In one patient the vulval mucosa healed completely (Figs 1b,c) and there was no further contact bleeding. We reduced the frequency of application of tacrolimus to once weekly in the first patient; the LP has not relapsed after 16 weeks. In the other patient the disease was controlled after 12 weeks, as judged by the patient and the investigator; she continues to use tacrolimus ointment three times weekly, which has controlled her LP during a follow-up of 20 weeks. While applying the tacrolimus the patients experienced a slight burning sensation. No other side-effects were noticed. The tacrolimus concentration was measured 2 months after initiation of the treatment and was lower than $1.5 \mu\text{g L}^{-1}$ in one patient and $4 \mu\text{g L}^{-1}$ in the other (trough concentration after three consecutive applications). At 11 h after dosing, the therapeutic trough range for oral tacrolimus in organ transplant recipients has been defined at $5\text{--}20 \mu\text{g L}^{-1}$. We are therefore below the systemic therapeutic level in our patients and do not expect serious adverse effects.

The conventional treatment for erosive LP of the mucosae is potent to very potent topical corticosteroids.^{1–3} However, this did not lead to a major improvement in our patients, and many patients suffer from disabling symptoms such as fused labia minora with a narrowed introitus vaginae and a bleeding and fused vagina. Earlier studies with topical cyclosporin in erosive LP gave conflicting results.^{4–6} Both cyclosporin and tacrolimus inhibit T-lymphocyte activation

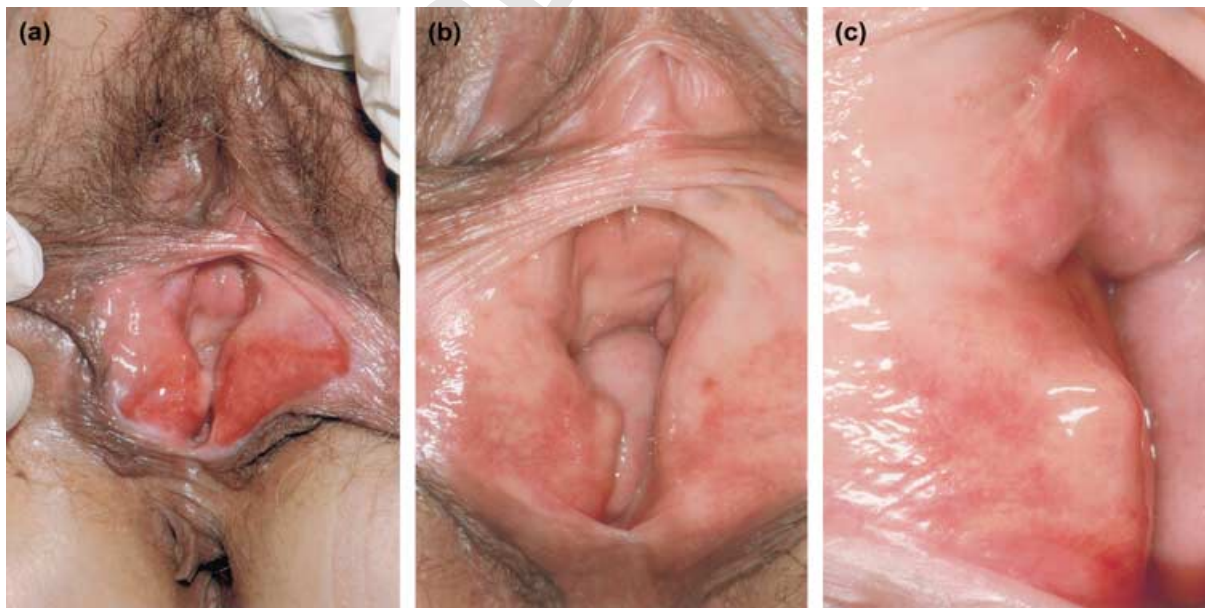


Figure 1. (a) Erosive vulval lichen planus before treatment; (b,c) condition of the vulva after 8 weeks of treatment with topical 0.1% tacrolimus.

in preventing interleukin-2 production. However, topical cyclosporin may have failed to provide acceptable clinical efficacy when used topically because of its poor skin penetration.⁷ Vente *et al.*⁸ and Lener *et al.*⁹ reported topical tacrolimus to be effective in mucosal LP (vulval and oral). We applied topical tacrolimus successfully in vaginal and vulval LP without serious side-effects. The long-term effect needs to be evaluated; it may be necessary to apply low-dose topical tacrolimus long-term in order to suppress the LP. However, this is the first time that a topical treatment has been shown to be effective in erosive LP. This therefore may prevent the disabling course of the disease in many women.

Topical tacrolimus ointment is available in the U.S.A and Japan; it is available via the International Pharmacy in Europe, but is expensive: 50 g of the ointment (Protopic ointment, Fujisawa, U.S.A) costs about 400 guilders (about £150). We decided to use a preparation suitable for the mucosa that was prepared by local pharmacists after discussing drug compatibility. However, we would prefer to use a manufactured preparation for reasons of drug compatibility and to ensure a constant concentration of tacrolimus. We are also unable to judge the shelf life of the 'home-made' ointment. If we are to recommend this very promising treatment for erosive LP of the mucosae it must be tested in larger groups, if possible in a randomized fashion.

Departments of Dermatology and
Gynaecology, Vrije Universiteit
Medical Center, PO Box 7057,
1007 MB Amsterdam,
the Netherlands
E-mail: G.Kirtschig@vumc.nl

G.KIRTSCHIG
A.J.VAN DER MEULEN
J.W.ION LIPAN
T.J.STOOF

References

- 1 Edwards L. Desquamative vulvitis. *Dermatol Clin* 1992; **10**: 325–37.
- 2 Ridley CM. Chronic erosive vulval disease. *Clin Exp Dermatol* 1990; **15**: 245–52.
- 3 Lewis FM. Vulval lichen planus. *Br J Dermatol* 1998; **138**: 569–75.
- 4 Bécherel P-A, Chosidow O, Boisnic S *et al.* Topical cyclosporine in the treatment for oral and vulvar erosive lichen planus: a blood level monitoring study. *Arch Dermatol* 1995; **131**: 495–6.
- 5 Itin P, Surber C, Buchner S. Lack of effect after local treatment with a new ciclosporin formulation in recalcitrant erosive oral lichen planus. *Dermatology* 1992; **185**: 262–5.
- 6 Francès C, Boisnic S, Pelisse M *et al.* Effet de la cyclosporine A sur les lichens érosifs muqueux: étude ouverte de 22 observations. *Ann Dermatol Venerol* 1991; **118**: 680.
- 7 Nasr IS. Topical tacrolimus in dermatology. *Clin Exp Dermatol* 2000; **25**: 250–4.
- 8 Vente C, Reich K, Rupprecht R, Neumann C. Erosive mucosal lichen planus: response to topical treatment with tacrolimus. *Br J Dermatol* 1999; **140**: 338–42.
- 9 Lener EV, Brieva J, Schachter M *et al.* Successful treatment of erosive lichen planus with topical tacrolimus. *Arch Dermatol* 2001; **137**: 419–22.

MARKED PROOF

Please correct and return this set

Any errors in this proof which have been noticed by the printer's reader have been marked in green. If you see any more printer's errors, please mark them in red: there is no charge for correcting these mistakes. For your own alterations, please use black or blue or any colour other than green or red. Please use the proof correction marks shown below for all alterations and corrections.

<i>Instruction to printer</i>	<i>Textual mark</i>	<i>Marginal mark</i>
Leave unchanged	... under matter to remain	Stet
Insert in text the matter indicated in the margin	⤴	New matter followed by ⤴
Delete	⤵ through matter to be deleted	⤵
Delete and close up	⤵ through matter to be deleted	⤵
Substitute character or substitute part of one or more word(s)	/ through letter or ⤵ through word	New letter or new word
Change to italics	— under matter to be changed	ƒ
Change to capitals	≡ under matter to be changed	≡
Change to small capitals	= under matter to be changed	=
Change to bold type	~ under matter to be changed	~
Change to bold italic	≡ under matter to be changed	≡
Change to lower case	Encircle matter to be changed	⊖
Change italic to upright type	(As above)	⊖
Insert 'superior' character	/ through character or ⤴ where required	γ under character e.g. γ
Insert 'inferior' character	(As above)	⤵ over character e.g. ⤵
Insert full stop	(As above)	⦿
Insert comma	(As above)	,
Insert single quotation marks	(As above)	γ and/or γ
Insert double quotation marks	(As above)	γ and/or γ
Insert hyphen	(As above)	Ⓜ
Start new paragraph	⤴	⤴
No new paragraph	~	~
Transpose	⤴	⤴
Close up	linking c letters	∩
Insert space between letters	⤴ between letters affected	#
Insert space between words	⤴ between words affected	#
Reduce space between letters	↑ between letters affected	↑
Reduce space between words	↑ between words affected	↑